

Use of the medicinal leech to salvage specialized skin jeopardized by venous impairment

P. J. Regan, J. O. Roberts, S. R. Sabapathy and A. H. N. Roberts

Department of Plastic and Reconstructive Surgery, Stoke Mandeville Hospital, Aylesbury, Bucks, UK

Introduction

The medicinal leech (*Hirudo medicinalis*) is a major asset to any plastic surgery department as it possesses unique properties which enable it to decongest venous compromised tissue. We report two cases where venous congestion of traumatically avulsed plantar skin was treated with leeches.

Case 1

A 27-year-old man was referred to the plastic surgery department having sustained a severe crush injury to his right foot when a bus ran over it. On examination there was extensive degloving of both the dorsal and plantar aspects of the foot with amputation of the great toe at the level of the metatarsal head, and of the second and third toes at midproximal phalangeal level (Figures 1 and 2).

At operation a limited wound excision was performed. The

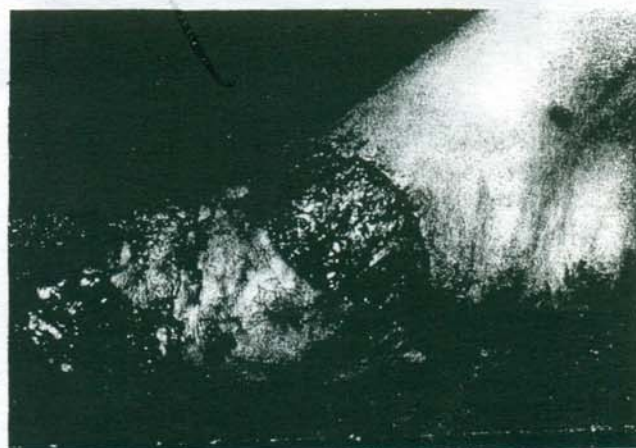

Figure 2. Extent of the degloving (Case 1).

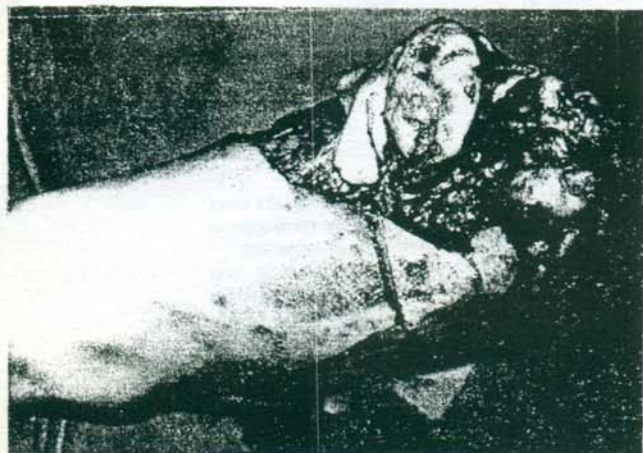


Figure 1. Extent of the degloving (Case 1).

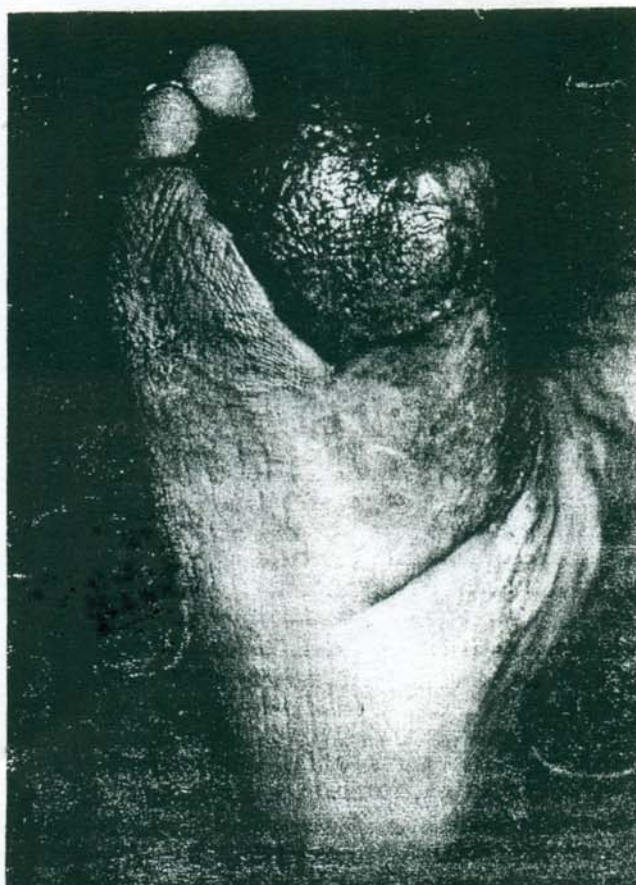

Figure 4. The final result (Case 1).

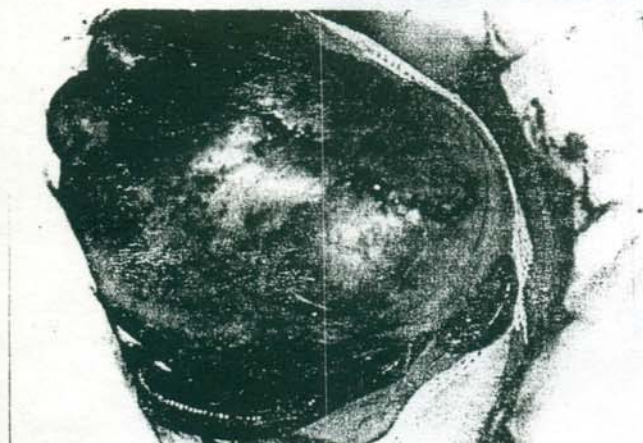

Figure 3. Leeches decongesting the degloved skin (Case 1).