



SIMULTANEOUS VOLAR AND DORSAL DISLOCATION OF PROXIMAL INTERPHALANGEAL JOINTS IN ADJACENT FINGERS - A CASE REPORT

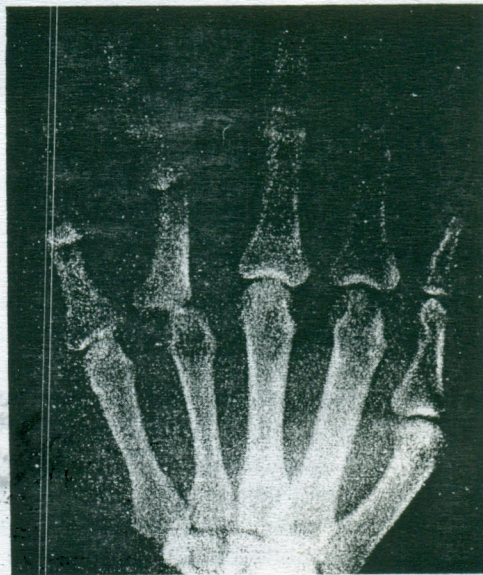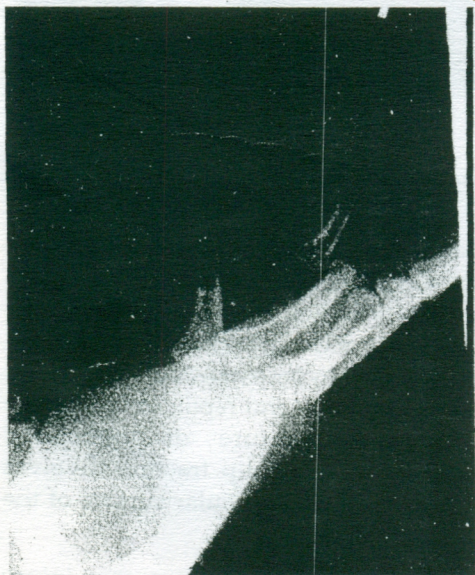S Raja Sabapathy, Vijay C Bose, C Rex and J Dheenadhayalan
Hand & Reconstructive Microsurgery Unit, Ganga Hospital, Coimbatore

SUMMARY. *Volar dislocation of PIP joint or MCP joint is a rare injury. They are seldom seen acutely and hence literature is sparse on the ideal method of management of these injuries. We had a patient who presented with a rare combination of volar dislocations of PIP and MCP joints of the ring finger with a classic dorsal dislocation of the PIP joint of the little finger. All dislocations underwent successful closed reduction in the acute stage followed by appropriate method of immobilisation and physiotherapy.*

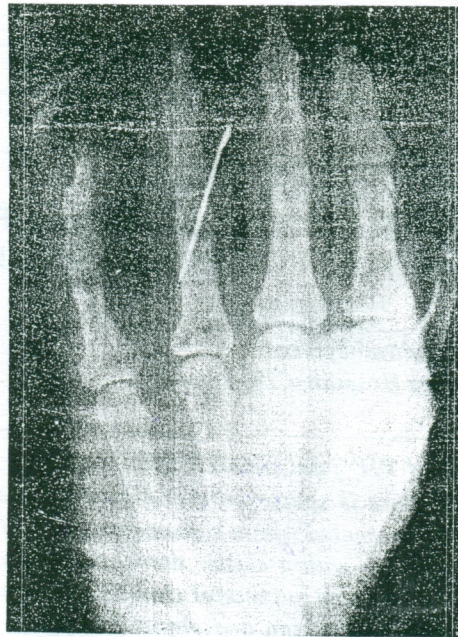
CASE REPORT

A 43 year old gentleman was seen seven hours after he fell off a bike. His right hand was swollen and he was unable to move the little and ring fingers. There were transverse lacerations on the volar aspect of the PIP joints of the ring and little fingers with abrasions on the dorsum. No definite deformity of any joint was apparent clinically due to oedema. X-ray revealed dorsal dislocation of the PIP joint of the little finger with volar dislocation of the PIP and MCP joints of the ring finger (Fig. 1 & 2). Under axillary block all the wounds were debrided and sutured. All dislocations were then

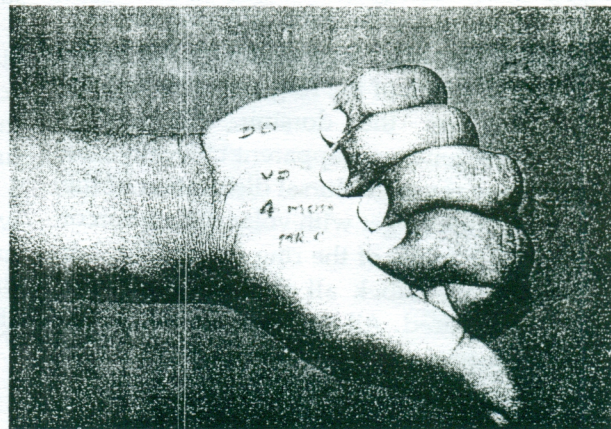
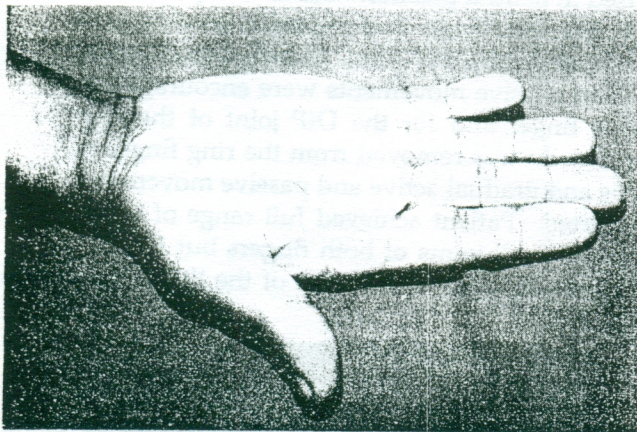
reduced in closed fashion. Reduction was easy. The reduction of the PIP joint of the ring finger appeared to be unstable. The PIP joint of the ring finger was stabilised in neutral position with an oblique K wire (Fig. 3). The little finger was treated in an extension block splint for the PIP joint. In two weeks gentle active and passive movements were encouraged in the little finger and for the DIP joint of the ring finger. K wire was removed from the ring finger in 5 weeks and gradual active and passive movements were started. Patient achieved full range of active movement in all joints of both fingers but for a 10 degree extension lag in PIP joint of the little finger (Figs. 4 & 5).



(Fig - 1 & 2) AP and Lat. radiographs showing volar dislocation of the PIP joint in ring finger and dorsal dislocation of the PIP joint in the little finger. Also note the volar dislocation of the MCP joint in ring finger.



(Fig - 3) Shows the reduced positions of all the dislocated joints.
The PIP joint in the ring finger has been transfixated
with K - wire after reduction



(Fig - 4 & 5) Shows the range of motion at 8 weeks post-op.

DISCUSSION

Dislocation of PIP joint is a potentially disabling injury if not treated adequately. Dorsal dislocation of the PIP joint is a common injury produced usually by hyperextension stress simultaneous with some degree of longitudinal compression. Rupture of the volar plate must necessarily occur along with this injury. The plate may be torn either at the junction of the membranous and fibrocartilaginous portions of the plate or at its distal attachment into the base of the middle phalanx. A small chip avulsion fracture may be asso-

ciated with the latter. These types of simple dislocations do not require open repair of the volar plate. They do well with buddytaping for 3-6 weeks which facilitates early active movement of the joint and prevents passive hyperextension. Open reduction, K-wire stabilisation and repair of volar plate are indicated only for fracture dislocations of the PIP joint where the volar lip fracture involves more than 20 per cent of the articular surface of the middle phalanx.

Volar dislocation of the PIP joint is a rare injury engendered from a longitudinal compressive force

acting on a semi-flexed middle phalanx. It is interesting to note that one incident has produced a dorsal dislocation and a volar dislocation of adjacent fingers in the case under study. To our knowledge such a combination of injuries in the same hand has not been reported earlier.

Spinner and Choi¹ in 1970 were the first to describe in detail the entire pathophysiology of a volar dislocation of the PIP joint. They reported 5 cases during a period of 12 years in the pilot article on this entity. They concluded that volar dislocations are associated with the rupture of the central slip, the collateral ligaments usually and sometimes the volar plate. They stressed that these soft tissue components of this injury pattern be recognized promptly and dealt with suitably. Four out of the five cases appearing in their report did not have a repair of the central slip and subsequently all four of them ended with a fixed boutonniere deformity. The one patient who had repair of the central slip and K-wire stabilisation in extension gradually regained his full range of movement. So on this basis they advocated open reduction and repair of central slip in all cases.

Recently Dray and Eaton² suggested that volar dislocation of PIP could be treated adequately with closed reduction and percutaneous pinning. This is based on the premise that, once reduced, volar PIP dislocations are equivalent to closed traumatic central slip injuries. Since central slip injuries could be treated by splinting, the same is applicable for volar PIP dislocation after reduction. We have followed this reasoning and proceeded to treat this patient with reduction and oblique K-wire stabilisation for 5 weeks. Though splinting of PIP may have proved adequate, we adopted pinning to ensure the purpose, as patient compliance is poor in our set up. An integral part of the post-operative physiotherapy was to encourage DIP joint movement at the time of PIP immobilisation.

Flexion of DIP causes lateral bands to elevate, and thereby preventing boutonniere deformity.

According to Green³ traumatic volar dislocations are of two types - pure volar and volar with rotary component. The case that we had was of the pure volar variety. This variety is easy to reduce in contrast to the one with rotary component where the head of the proximal phalanx usually buttonholes through the extensor mechanism.

In multiple joint dislocations, even when coexistent in the same hand, each must be treated on its own merit based on the precise pathology. Pure volar dislocation, being easily reducible, was treated by immobilisation for 5 weeks and the dorsal dislocation was managed with extension blocking splint ending in a satisfactory result.

References

- 1 **Spinner M, Choi BY.** Anterior dislocations of proximal interphalangeal joint - A cause of rupture of central slip of the extensor mechanism. *J Bone Joint Surg.* 1970; 52A:1329-1336.
- 2 **Dray GJ, Eaton RG.** Dislocations and Ligament Injuries in the Digits In: Green DP (Ed.) *Operative Hand Surgery*, 3rd Ed., Vol. 1, Edinburgh: Churchill Livingstone, 1993:774.
- 3 **Green DP.** Dislocations and Ligamentous Injuries of the Hand In: Evarts (Ed.) *Surgery of the Musculoskeletal System*, 2nd Ed., Vol.1. Edinburgh: Churchill Livingstone, 1990:396

Authors

Dr. S Raja Sabapathy, MS, MCh, DipNB, FRCS(Ed), Consultant Plastic, Hand and Microsurgeon
Dr. Vijay C Bose, MS (Ortho), Registrar
Dr. C Rex, MS (Ortho), Formerly Registrar
Dr. J Dheenadhayalan, MS (Ortho), Registrar

Hand and Reconstructive Microsurgery Unit, Ganga Hospital, Coimbatore.

Requests for reprints to Dr. S Raja Sabapathy, Ganga Hospital, Swarnambika Layout, Coimbatore - 641 009.

Paper received : 2 March 1994

Accepted : 12 May 1994