



REVERSE DIGITAL ARTERY ISLAND FLAP FOR FINGER-TIP DEFECTS

S Raja Sabapathy, S Suresh Babu and Anil K Agarwal
Hand & Reconstructive Microsurgery Unit, Ganga Hospital, Coimbatore

SUMMARY : Five finger-tip amputations and two fingers with pulp-loss were covered with reverse digital artery island flaps from the same finger. The flap was successful in all cases and provided cosmetically and functionally acceptable results. One patient had venous congestion, but the flap survived. This flap would be particularly useful when the nature of injury precludes the use of local advancement flaps and cross-finger flaps.

INTRODUCTION

Soft-tissue coverage of the finger-tip requires stable and sensate skin. When the nature of the defect demands a flap, straight or oblique advancement flaps of volar skin or cross finger flaps are commonly used. Advancement flaps are mainly applicable when the defect is either transverse or dorsal oblique, while cross finger flaps are preferred for volar oblique defects exposing tendon or bone. The cross finger flap has the disadvantage of improper colour match and of being a two-stage procedure. An island of volar skin raised from the base of the finger with one digital artery can be used as a reverse flow flap to cover such finger tip defects^{1,2}.

SURGICAL TECHNIQUE

The defect is measured and it is marked at the base of the finger centering on the course of the digital artery. The less contact side of the finger is chosen. Since the digital artery is to be divided, integrity of the other digital artery is checked by a digital Allen test. The flap is first raised by making incisions on the sides and proximally. The digital neurovascular bundle is identified and the nerve is separated. Artery is then divided after ligation. To prevent the artery from shearing off the flap, a tagging suture is put to the skin. The flap is then raised, carefully separating it from the digital nerve. The distal skin incision is then made to complete the island. By zig zag incisions made upto the defect distal to the flap, the pedicle is dissected. Since digital arteries are not accompanied by veins, this flap for its venous drainage depends on small venules in the subcutaneous tissue. Hence skeletonization of the artery during pedicle

dissection must be avoided. The pedicle is dissected upto the middle of the middle phalanx and the flap is shifted to cover the defect. It is important that the pedicle is dissected well so that there is no tension after the inset. The donor site could be closed or covered with a graft. The rest of the wound is directly closed and if there is tension beyond the pivot point, the pedicle is covered with a graft.

ILLUSTRATIVE CASE REPORTS

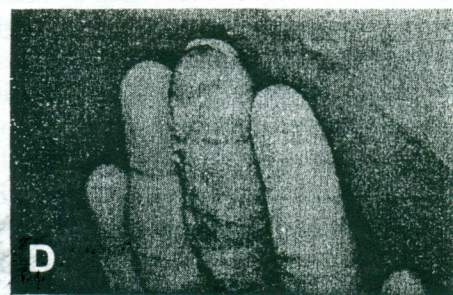
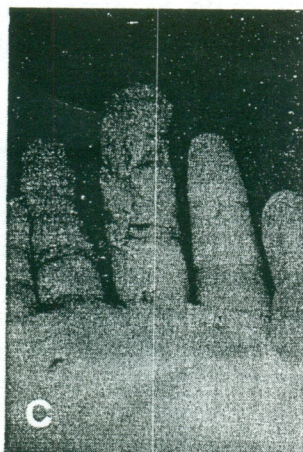
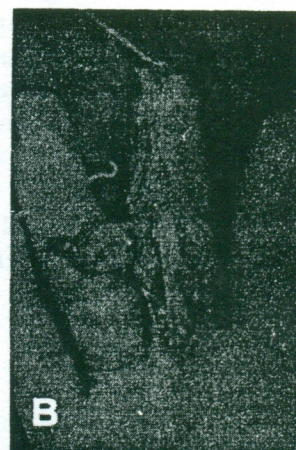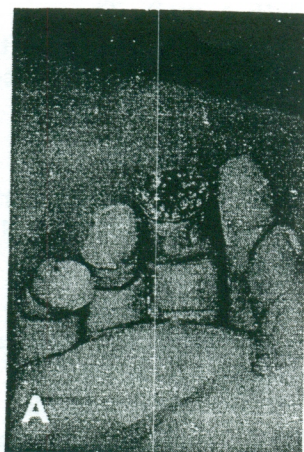7 reverse digital artery flaps have been performed and the details are summarized in Table 1. Two cases are illustrated below:

Case No. 1 : A 21 year old male sustained a total crush amputation of the tip of his right middle finger when a heavy object fell on the hand. There was loss of most of the pulp and the distal phalanx tuft (Fig 1A). A reverse digital artery flap was raised from the ulnar side of the base of the same digit (Fig 1B). After insetting the flap the secondary defect could be closed directly (Fig 1C). At 7 months follow-up the flap has healed well and the patient uses the digit in all daily activities (Fig 1D).

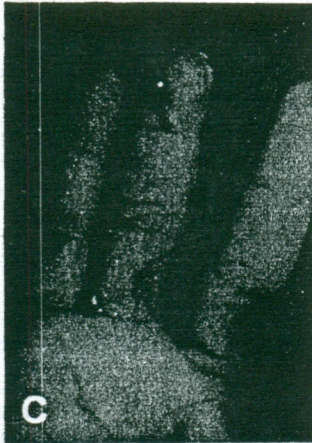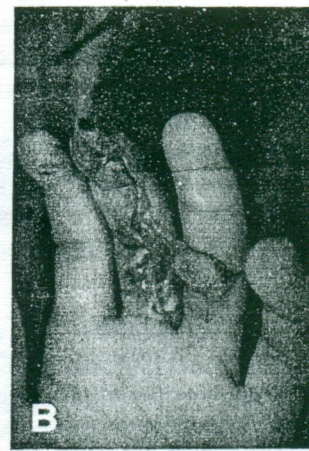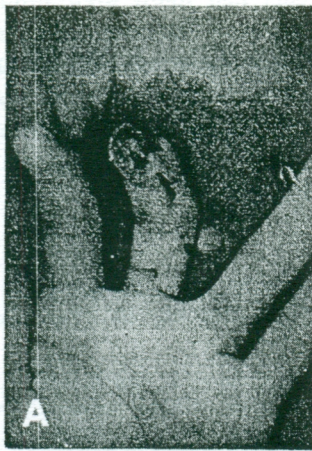Case No. 6 : A 17 year old saw-mill worker sustained a crush-amputation of the tip of his left middle finger in a lathe machine resulting in pulp-loss and nail-bed injury (Fig 2A). The protruding distal phalanx was trimmed by 2 mm, and a reverse digital artery flap was raised on the ulnar aspect of the base of the same finger (Fig 2B). The wound was débrided, the nail-bed repaired and the flap given inset. The secondary defect was covered with split-skin graft. The flap took well and after nine months shows good colour match as well as contour (Fig 2C & D).

Table - 1

Case No	Sex	Age	Affected Finger	Other Fingers	Site of Skin Defect	Size of Flap	Donor Site	Complication	Result
1	M	21	(R) Middle	-	Amputation stump	2cm x 1.5cm	Ulnar	-	Good
2	M	23	(L) Ring	Yes (4 finger injury)	Amputation stump	1.5cm x 1.8 cm	Ulnar	-	Good
3	M	40	(L) Little	-	Amputation stump	1.2cm x 1.5cm	Ulnar	-	Good
4	M	40	(R) Middle	-	Pulp Loss	1.5cm x 1.8cm	Ulnar	Epidermal Peeling	Good
5	M	23	(R) Index	-	Amputation stump	2cm x 1.5 cm	Ulnar	-	Good
6	M	17	(L) Middle	-	Pulp Loss	1.8cm x 1.5cm	Ulnar	-	Good
7	M	26	(L) Ring	Yes (4 finger injury)	Amputation stump	1.5cm x 1.8cm	Ulnar	-	Good



(Fig - 1) (A) Pre-operative photograph showing the extent of soft-tissue loss (B) Intra-operative photograph with the flap raised (C) Flap inset completed and donor defect closed directly (D) Follow-up at 7 months



(Fig - 2) (A) Pre-operative photograph with the flap marked (B) Intra-operative photograph with the flap raised (C) 9 months follow-up, front view (D) 9 months follow-up, side view

DISCUSSION

Flaps that are popular for treating finger-tip injuries include the straight V-Y advancement flap of Atasoy³, the oblique triangular flap of Venkataswamy⁴ and cross finger flaps. The latter is quick and easy, provide stable cover but has the disadvantage of cosmetic mismatch and of being a two-stage procedure. In these circumstances, the reverse digital artery island flap is a good alternative. Neurovascular pedicle island flaps were popularised by Littler, and later Rose reported the use of an island flap containing vascular pedicle alone with digital nerve preservation⁵. Weeks and Wray described an island flap in which proximal end of the digital artery was ligated and the flap transposed to cover dorsal skin loss over the PIP joint⁶. Based on this report, Kojima et al and Lai et al have designed the reversed digital artery island flap as described here to cover finger tip defects.^{1,2}

This flap depends on the blood supply received through anastomoses present between the ulnar and radial side digital arteries. Deep arcuate anastomoses exist approximately at the level of the middle of both proximal and middle phalanges. Kojima¹ investigated this 'digital palmar arch' in cadavers and found that it exists in the proximal 2/3 of the proximal phalanx and lies halfway along the middle phalanx. It perforates the deepest part of the side of the flexor tendon sheath to lie beneath the check rein ligament of the volar plate and passes between the posterior wall of the tendon sheath and periosteum to form the arch. This anatomical fact is utilised in designing the reverse digital artery flap. Kojima et al in their report of 7 cases, reported congestion and marginal necrosis in 3 cases¹. Venous congestion is always a problem in most reverse flow flaps. It is particularly significant in the fingers since the digital arteries are not accompanied by a vein. In almost all our cases we

found thin subcutaneous veins at the time of raising the pedicle. We carefully preserved these veins and possibly because of this we did not encounter venous congestion except in one case where epidermal peeling did occur initially. If there is difficulty in direct skin closure over the pedicle, we apply a skin graft over it. This is taken from the palm (hypothenar or thenar eminence) and gives good cosmetic results. It is important to inset the flap without tension.

The donor site could be directly closed if the horizontal dimension of the flap is small. This is more so if the proximal margin of the flap is near the crease of the base of the finger. Since the pedicle is reversed, direct closure of the donor defect does not produce any tension on the pedicle. If the defect is larger, full thickness skin graft or thick SSG is applied. The final result is cosmetically good by both methods. Zig-zagging the incision is important to prevent linear scar contracture.

Raising the flap is not difficult once the anatomy is familiar and it takes about 20 minutes. The chief advantage of this flap is that it provides glabrous skin at the finger tip which is cosmetically superior in comparison to a cross finger flap. It is not a sensate flap. Dellon has shown that the ultimate quality of fine sensation depends on the presence of a sufficient population of skin receptors⁷. Theoretically the volar skin in this flap has more receptor density than dorsal skin of cross-finger flaps, and ingrowth of nerve fibres from the recipient bed and wound margin should provide adequate sensation. Four of our cases have been followed up for more than 9 months. They have sufficient sensation for normal activities and it is our feeling that the sensation in the reverse digital artery flap is better in quality and acquired earlier than cross-finger flaps. However this is only our impression, and has to be confirmed by long-term follow-up.

Two of our patients had multi digit injuries which negated the option of a conventional cross finger flap. In such difficult situations, the reverse digital artery island flap is a good choice. Its use has recently been extended as a pedicled cross finger flap and for restoration of sensation utilising the dorsal sensory branch⁸.

References

1. Kojima T, Tsuchida Y, Hirase Y and Endo T. Reverse vascular pedicle digital island flap. *Br J Plast Surg* 1990; 43: 290-295.
2. Lai C S, Lin S D, Chou C K and Tsai C W. A versatile method for reconstruction of finger defects : Reverse digital artery flap. *Br J Plast Surg* 1992; 45:443-453.
3. Atasoy E, Ioakimidis E, Kasdan M L, Kutz S E, Kleinert H E. Reconstruction of amputated finger tip with a triangular volar flap. A new surgical procedure. *J Bone Joint Surg* 1970; 52A:921-926.
4. Venkatasamy R, Subramanian N. Oblique triangular flap : A new method of repair for oblique amputations of the finger tip and thumb. *Plast Reconstr Surg* 1980; 66:296-300.
5. Rose E H. Local arterialized island flap coverage of difficult hand defects preserving donor digit sensibility. *Plast Reconstr Surg* 1983; 72:848.
6. Weeks P M and Wray R C. Management of acute hand injuries. St. Louis Mosby 1973; 140.
7. Dellon A L. Evaluation of sensibility and reeducation of sensation in the hand. Baltimore, Williams and Wilkins 1981; 169.
8. Lai CS, Lin SD, Tsai CC, Tsai CW. Reverse digital artery neurovascular cross-finger flap. *J Hand Surg* 1995; 20A: 397-402.

Authors

Dr S Raja Sabapathy, MS, M Ch(Plastic), FRCS(Ed) Dip. NB, Consultant

Dr S Suresh Babu, MS(Ortho), Registrar

Dr Anil K Agarwal, MS, M Ch (Plastic), Registrar

Hand and Reconstructive Microsurgery Unit, Ganga Hospital, Coimbatore.

Request for reprints to Dr. S Raja Sabapathy, Ganga Hospital, Swarnambika Layout, Ramnagar, Coimbatore - 641 009.